

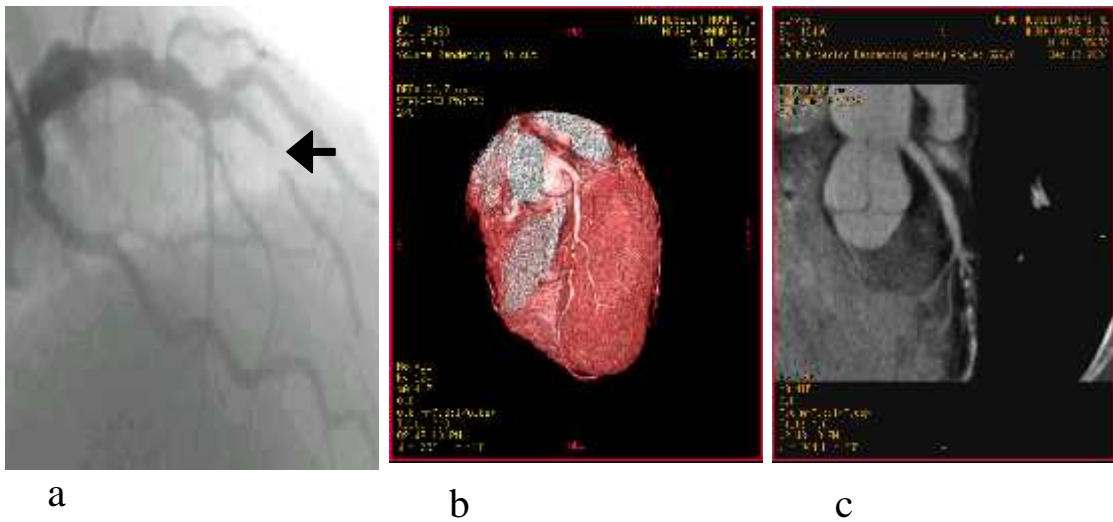Fig. 1. Conventional coronary angiogram (a) showing subtotal post-second diagonal left anterior descending artery occlusion with late filling (Arrow). Excellent image quality of the lesion is displayed by the corresponding three-dimensional volume rendering reconstruction (b) and the maximum intensity projection images (c)

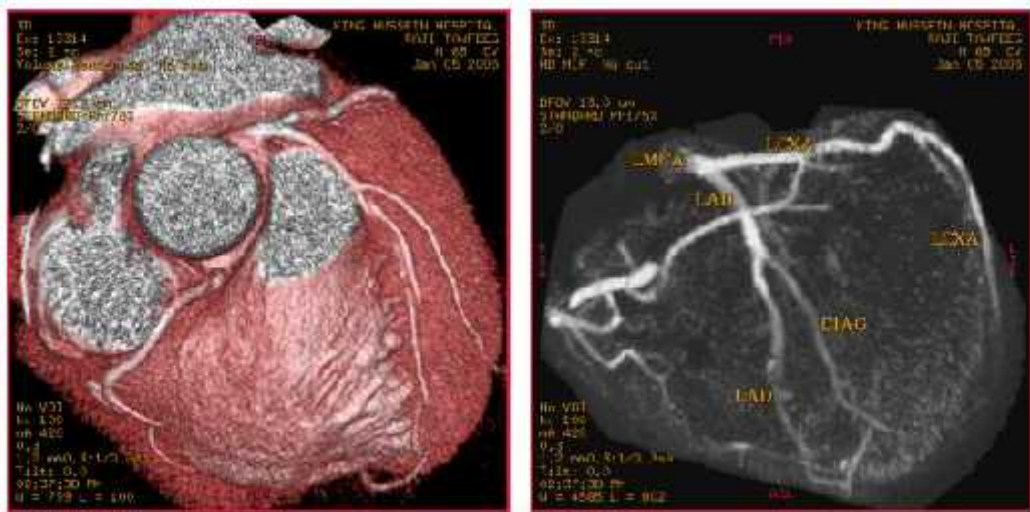


Fig. 2 Three Dimensional volume rendering reconstruction images displaying normal whole coronary artery tree